



ACUTE PARAPLEGIA DUE TO ACREMONIUM VERTEBRAL OSTEOMYELITIS – CASE REPORT WITH REVIEW OF LITERATURE

Raju Karuppal* Anwar Marthya** Jacob Alappat*** Premkumar**** Rajendran V Raman*****
Sandhya Somasundaran*****

*Associate Professor, Dept of Orthopaedics, Govt. Medical College, Kerala

**Associate Professor, Dept of Orthopaedics, KMCT Medical College, Kerala

***Professor of Neurosurgery, Govt. Medical College, Kozhikode, Kerala

****Assistant Professor of Neurosurgery, Govt. Medical College, Kerala

*****Professor of Radiodiagnosis, Govt. Medical College, Kerala

*****Assistant Professor, Dept of Ophthalmology, Govt. Medical College, Kerala

Abstract

Fungal vertebral osteomyelitis is rare. *Acremonium* is a saprophytic fungi producing opportunistic infections in immunocompromised subjects. Infection causing vertebral osteomyelitis and epidural abscess with paraplegia is not reported. We describe a patient who had *Acremonium falciforme* myositis of the thoracic paraspinal muscles and later presented with vertebral osteomyelitis, epidural infection and paraplegia.

Keywords: *Acremonium, Vertebral Osteomyelitis, Epidural Fungal Infection, Paraplegia, Amphotericine –B.*

Case Report

A 62 year old woman presented with pain and a diffuse swelling of the thoracic paraspinal region in June 2010. Her WBC count was 10850, ESR 38 and CRP 6.4. X ray of thoracic spine was normal. MRI showed hyper intense signal in the T2 weighted image, contrast showed irregular patchy enhancement in the paraspinal muscle and the vertebrae were normal. The tissue biopsy from paraspinal muscle confirmed fungal myositis. The fungus was identified as *Acremonium falciforme* species. There was no history of direct trauma or any intravenous drug intake. She was not immunocompromised. She was treated with oral fluconazole (150mg daily) for a period of 8 weeks and relieved of her symptoms and the paraspinal swelling partially subsided. In July 2011 she again presented with similar symptoms at the same site with multiple puckering lesions over the skin (Figure. 1). Her vertebral radiology was normal at that time also. She responded well to the same oral antifungal drug for a period of 8 weeks.

Then she has not come for follow up treatment. She had 3 episodes of swelling and redness at the same site, which was managed by her family doctor with antibiotics and analgesics.

In September 2013, she was brought to the emergency room with sudden onset of paraplegia. She was a febrile; there was thoracic spine tenderness over D4 vertebra with a diffuse swelling over the mid thoracic region extending to the paraspinal region. She had paraplegia with urinary and fecal incontinence. Her sensory level was at D6. Her WBC count was 18600 cells, ESR 76mm/hr, C-reactive protein level of 24.7 mg/dL with normal liver and renal function test.

CT scan of the dorsal spine demonstrated lytic lesions on the D4, D5, D6 vertebral body and posterior elements with posterior epidural soft tissue causing severe cord compression. (Figure. 2).

MRI showed altered marrow changes in D4, D5, and D6 vertebra with large posterior epidural soft tissue of intermediate signal causing severe cord compression (Figure. 3).

The patient underwent laminectomy and excision of sequestered bone and debridement of the necrotic tissue at the epidural space extending the dural sac, to relieve the compression over the spinal cord. Histopathological examination showed elongated hyphae and spores on methenamine silver and periodic acid-Schiff stains (FIG 4). Cultures were negative for bacteria and acid fast bacilli, but growth of *Acremonium* species of fungus were found.

The patient was then treated with intravenous liposomal amphotericin B therapy over a period of 3 weeks, followed by oral itraconazole for 16 weeks. Her back pain slowly abated, and by four months the ESR became normal. The patient remains paraplegic and bound to the wheel chair, probably due to the permanent ischemic damage of the spinal cord.



Discussion

Fungal osteomyelitis is a rare disease. Fungal bone and joint diseases are increasing due to the use of central venous catheters, broad-spectrum antibiotics and immunosuppression [1]. There have been a few reports of infection due to *Acremonium* species osteomyelitis in a bone marrow transplant recipient [1–3]. Definitive diagnosis relies on tissue biopsy. Successful treatment can be achieved by surgical debridement and therapy with amphotericin B.

Of the many species of *Acremonium*; *Acremonium falciforme*, *Acremonium kiliense*, *Acremonium strictum*, and *Acremonium recifei* have been implicated in infections. *Acremonium* are filamentous fungi often isolated from soil and plant debris. Colonies are white to pale gray and velvety, becoming cottony as they mature. They grow slowly in Sabouraud dextrose agar. [4, 5]. In this case culture showed crescentic, nonseptate conidia, which is characteristic of *Acremonium falciforme*.

They commonly cause foot or corneal infections following penetrating injuries in agriculture workers. *Acremonium* species infections are causing opportunistic pathogens in immunocompromised patients. Our patient did not have any immune deficiency state. To our knowledge only two cases of osteomyelitis and two cases of septic arthritis caused by *acremonium* species have been reported so far [6,7]. In one of the case of osteomyelitis of the calvarium, *Acremonium kiliense* was isolated. The patient was successfully treated with amphotericin B and ketoconazole in addition to craniectomy [8]. The second case was reported in a 9-year-old immunocompromised patient had tibial osteomyelitis caused by *Acremonium strictum* which was treated by surgical debridement and therapy with amphotericin B followed by voriconazole [9].

As *Acremonium* infection is rare the optimal therapy has not been established.

Amphotericin B, ketoconazole, itraconazole, fluconazole, 5-fluorocytosine, voriconazole, and combinations of these antifungal drugs have been used with variable success. Amphotericin B has been most commonly used in treating serious infections. [10]. Drug resistance has been reported to amphotericin B, ketoconazole, and itraconazole [11].

There were no risk factors for this invasive fungal infection in our patient. This case report highlights the vertebral osteomyelitis with epidural infection and acute paraplegia. To the best of our knowledge there is no similar report in English literature.

Conflicts of Interest

The authors declare that we do not have any financial and other conflicts of interest that might bias the work.

References

1. Kohli R, Hadley S. Fungal arthritis and osteomyelitis. *Infect Dis Clin North Am* 2005; 19:831–51.
2. Arias F, Mata-Essayag S, Landaeta EM, et al. *Candida albicans* osteomyelitis: case report and literature review. *Int J Infect Dis* 2004; 8:307–14.
3. Vaishya S, Sharma M. Spinal aspergillus vertebral osteomyelitis with extradural abscess: case report and review of literature. *Surgical Neurology* 2004; 61:551–5.
4. Fincher RM, Fisher JF, Lovell RD, Newman CL, Espinel-Ingroff A, Shadomy HJ. Infection due to the fungus *Acremonium* (cephalosporium). *Medicine (Baltimore)* 1991; 70:398–409.
5. Gupta AK, Summerbell RC. Combined distal and lateral subungual and white superficial onychomycosis in the toenails. *J Am Acad Dermatol* 1999; 41:938–44.
6. Ward HP, Martin WJ, Ivins JC, Weed LA. *Cephalosporium* arthritis. *Proceedings of the Staff Meetings of the Mayo Clinic* 1961; 36:43.
7. Szombathy SP, Chez MG, Laxer RM. Acute septic arthritis due to *Acremonium*. *J Rheumatol* 1988; 15:714-5.
8. Brabender W, Ketcherside J, Hodges GR, Rengachary S, Barnes WG. *Acremonium kiliense* osteomyelitis of the calvarium. *Neurosurgery* 1985; 16:554–6.
9. Miyakis S, Velegraki A, Delikou S, et al. Invasive *Acremonium strictum* infection in a bone marrow transplant recipient. *Pediatr Infect Dis J* 2006; 25:273–5.
10. Chang HY, Huang LM, Hsueh PR, et al. *Acremonium* pyomyositis in a pediatric patient with acute leukemia. *Pediatr Blood Cancer* 2005;
11. Rotowa NA, Shadomy HJ, Shadomy S. In vitro activities of polyene and imidazole antifungal agents against unusual opportunistic fungal pathogens. *Mycoses* 1990; 33:203-11.



Legends

Fig 1: Clinical Photo of the Patient Showing Multiple Puckering Lesions over the Skin

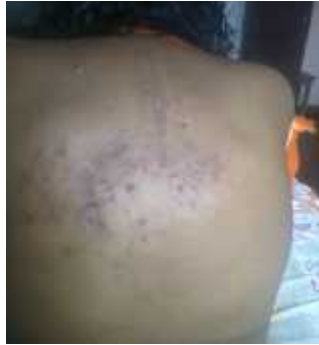

Fig 1: Radiographs of Thoracic Spine Showing Destruction and Lytic Lesion.

Fig 2: CT scan of thoracic spine showing lytic lesions on the D4, D5, D6 vertebral body and posterior elements with posterior epidural soft tissue causing severe cord compression.

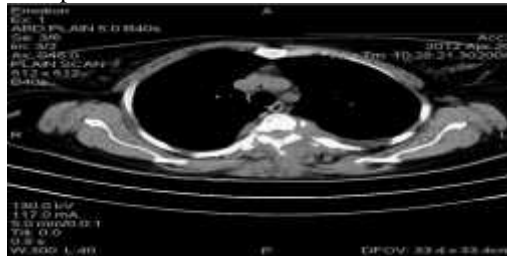


Fig 2: CT scan of Thoracic Spine Showing

Fig 3: MRI showing altered marrow changes in D4, D5, and D6 vertebra with large posterior epidural soft tissue of intermediate signal causing severe cord compression

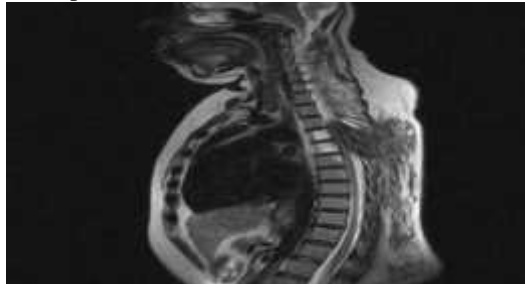


Fig 3: MRI showed

Fig 4: Histopathological examination showed elongated hyphae and spores on methenamine silver and periodic acid-Schiff stains

